



# Combined Eyelid and Strabismus Surgery: Examining Conventional Surgical Wisdom

Michael S. McCracken, MD; Jonathan D. del Prado, MD; David B. Granet, MD; Leah Levi, MBBS;  
Don O. Kikkawa, MD

## ABSTRACT

**Purpose:** To determine whether satisfactory results of both eyelid surgery and strabismus surgery can be obtained when these procedures are performed in the same setting in selected patients.

**Methods:** Nine patients (16 eyelids) who had undergone surgery in the same setting for eyelid malposition and strabismus of the horizontal rectus muscles, with or without concurrent vertical rectus muscle surgery, were retrospectively reviewed. Eyelid malposition surgery success was defined as a postoperative margin reflex distance (MRD<sub>1</sub>) within 1 mm of the target. Strabismus surgery success was defined as a postoperative deviation within 8 prism diopters of orthophoria or a decrease in binocular diplopia if the patient had a less than 8 prism diopters deviation in primary gaze preoperatively.

**Results:** Eyelid retraction repair was performed on 13 upper eyelids, levator advancement was performed on 2 eyelids, and frontalis suspension was performed on 1 eyelid. Four patients underwent bilateral medial rectus recession and the remaining 5 patients received varying strabismus surgery. Four

## EDUCATIONAL OBJECTIVES

1. To review the current recommendations for the timing of eyelid and strabismus surgery and to examine their rationales.
2. To identify the indications for same-setting eyelid and strabismus surgery.
3. To examine the success rate of same-setting eyelid and strabismus surgery compared to staged surgery.

patients received adjustable sutures. Mean follow-up was 11 months. Postoperatively, 13 of 16 eyelids (81%) achieved an MRD<sub>1</sub> within 1 mm of the target. Eight of 9 patients (89%) demonstrated satisfactory strabismus correction.

**Conclusion:** Combined eyelid malposition and strabismus surgery can be successfully performed in selected cases, particularly when the strabismus surgery involves the horizontal recti muscles. Combined surgery is not recommended in cases that do not involve the horizontal recti muscles.

**[J Pediatr Ophthalmol Strabismus 2008;45:000-000.]**

*From the Division of Ophthalmic Facial Plastic and Reconstructive Surgery (MSM, JDD, DOK); University of California–San Diego Thyroid Eye Center (DBG, LL, DOK); and the Division of Pediatric Ophthalmology and Strabismus (DBG), Department of Ophthalmology, University of California–San Diego, La Jolla, California.*

*Originally submitted September 14, 2006.*

*Accepted for publication July 6, 2007.*

*Presented as a poster at the American Society of Ophthalmic Plastic and Reconstructive Surgery Annual Fall Scientific Symposium in Orlando, Florida, October 2002.***AQ1**

*Address correspondence to Michael S. McCracken, MD, Colorado Laser Surgeons, 55 Madison Street #300, Denver, CO 80206.*

*Drs. McCracken, del Prado, Granet, Levi, and Kikkawa have disclosed no relevant financial relationships.*

## INTRODUCTION

Conventional surgical wisdom dictates that staged reconstructive surgery should begin with orbital surgery, followed by ocular muscle surgery and then eyelid surgery.<sup>1</sup> Each step may be omitted if not indicated. Correction of each abnormality may subsequently affect the following step. Although this is particularly true regarding the effect of vertical extraocular muscle surgery on eyelid position, eyelid surgery is often delayed until after any extraocular muscle surgery.

Vertical rectus muscle surgery has been shown to affect the position of the contiguous eyelid.<sup>2-4</sup> This is because the inferior rectus<sup>5</sup> and superior rectus<sup>6,7</sup> have attachments to the lower and upper eyelid, respectively. Surgery on these muscles shifts those attachments and thus may shift eyelid position.

For many patients, the prospect of having multiple operations over the course of several months is time-consuming, costly, difficult, and exhausting. In addition, the risk of multiple anesthetics cannot be ignored.

The possibility of performing combined eyelid and muscle surgery is appealing to some patients because it circumvents many of the previously mentioned disadvantages of staged surgeries. This applies to any patient with combined eyelid and muscle pathology, whether from thyroid-related orbitopathy, trauma, or developmental causes. This study sought to determine whether combined eyelid and strabismus surgery could be successfully performed in a single surgical setting, especially for procedures involving horizontal rectus muscle surgery.

## PATIENTS AND METHODS

The University of California–San Diego Human Subjects Program approved data collection for this study. All patients presented to a university-based tertiary referral center. The margin reflex distance (MRD<sub>1</sub>), the distance between the upper eyelid and the corneal light reflex, was used to record the preoperative upper eyelid position. Ocular alignment measurements were obtained using the alternate cover test with the patient fixating on a distant target. All patients had stable measurements for at least 6 months prior to surgery. Eyelid surgery (DOK) and strabismus surgery (DBG) were each performed by a single surgeon.

The patients were observed for an average of 11 months (range: 1 to 29 months). All patients demonstrated stability in eyelid and alignment measurements preoperatively. Postoperative eyelid measurements and extraocular motility measurements were made in the same manner as the preoperative measurements. For eyelid surgery, the target postoperative MRD<sub>1</sub> was 4 mm, except in two unilateral cases (patients 5 and 7), where the MRD<sub>1</sub> of the nonsurgical eyelid was the target. Success was defined as a postoperative MRD<sub>1</sub> within 1 mm of the target. For strabismus surgery, success was defined as postoperative deviation within 8 prism diopters of orthophoria or (for 2 patients with less than 8 mm of deviation preoperatively) a decrease in binocular diplopia.

## RESULTS

The medical records of 9 patients (8 females and 1 male) who underwent eyelid and rectus muscle strabismus surgery in the same setting were retrospectively reviewed. The average patient age was 44 years (range: 17 to 79 years).**AQ2** Seven of the patients had thyroid eye disease and 2 had third cranial nerve palsy.

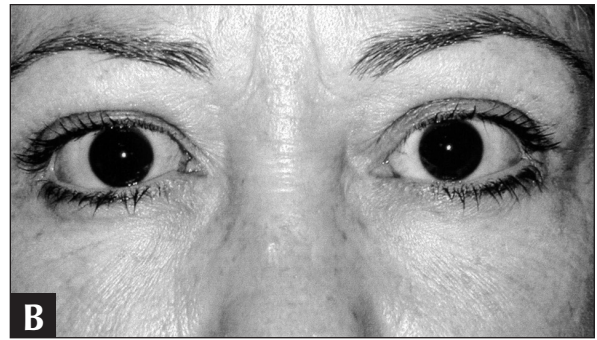
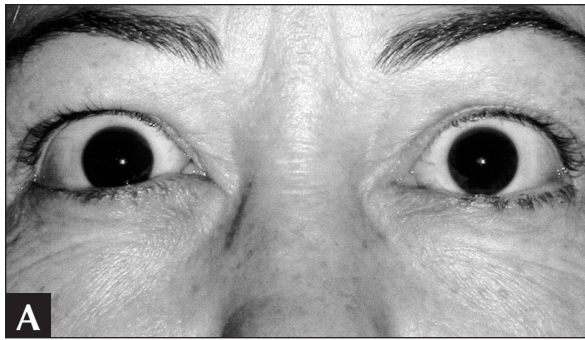Surgery was performed on 16 eyelids of the 9 patients. Surgery was performed under general anesthesia in 5 patients, under monitored anesthesia care in 3 patients, and under monitored anesthesia care for the eyelids followed by general anesthesia for the extraocular muscles in 2 patients (patients 2 and 9). Eyelid surgery was performed before extraocular muscle surgery in 7 of 16 eyelids and after extraocular muscle surgery in 9 of 16 eyelids. Surgeon availability was the main determinant of which surgery preceded the other. In awake patients, intraoperative eyelid adjustments were made with the patient fixating with the dominant eye.

Eyelid surgery consisted of levator and Mueller's muscle recession to treat eyelid retraction in 13 upper eyelids, levator advancement to correct ptosis in 2 eyelids, and silicone frontalis suspension to correct ptosis in 1 eyelid. Eyelid retraction repair was performed in a manner similar to that previously described.<sup>8</sup> No adjustable sutures were used for eyelid surgery. All patients were treated with muscle surgery in the same surgical setting. Except for the patient who received posterior fixation surgery, all

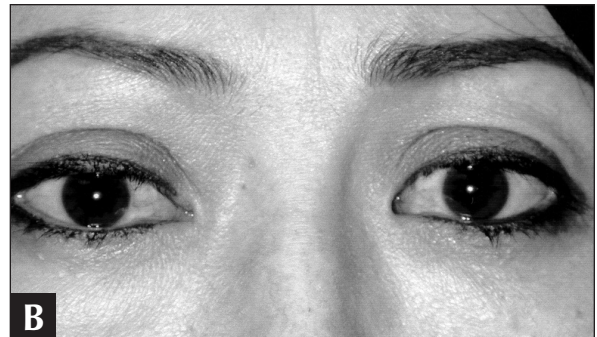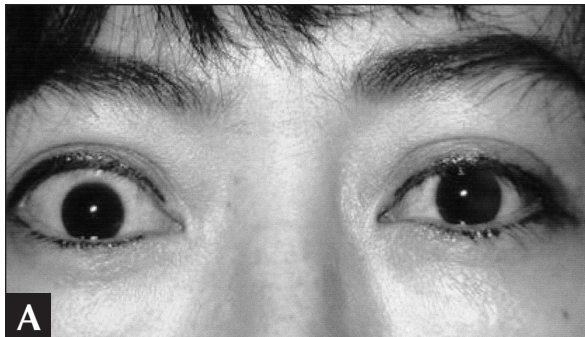TABLE  
**PREOPERATIVE MEASUREMENTS, POSTOPERATIVE MEASUREMENTS, AND SURGERY PERFORMED**

| Patient/<br>Eyelid | Age at<br>Surgery<br>(Y) | Follow-<br>up (Mo.) | Diagnosis | Anesthesia  | First<br>Surgery | MRD <sub>1</sub> | Post<br>MRD <sub>1</sub> | Target<br>MRD <sub>1</sub> | Eyelid<br>Revision<br>Surgery | Muscle Surgery            | Preop<br>Deviation | Postop<br>Deviation |
|--------------------|--------------------------|---------------------|-----------|-------------|------------------|------------------|--------------------------|----------------------------|-------------------------------|---------------------------|--------------------|---------------------|
| 1/RUL              | 47                       | 8                   | TED       | MAC         | Strabismus       | 9                | 4                        | 4                          | No                            | 4 mm BMR                  | 26 ET              | 6 ET                |
| 1/LUL              | 47                       | 8                   | TED       | MAC         | Strabismus       | 10               | 5                        | 4                          | No                            | 4 mm BMR                  | 26 ET              | 6 ET                |
| 2/RUL              | 44                       | 1                   | TED       | MAC         | Strabismus       | 6.5              | 1                        | 4                          | Recommended                   | 3.5 mm BMR<br>w/adj       | 12 ET              | Ortho               |
| 2/LUL              | 44                       | 1                   | TED       | MAC         | Strabismus       | 6                | 2                        | 4                          | Recommended                   | 3.5 mm BMR<br>w/adj       | 12 ET              | Ortho               |
| 3/RUL              | 40                       | 5                   | TED       | MAC/General | Eyelid           | 6                | 4                        | 4                          | No                            | RMR rec/RIR rec           | 8 ET               | Ortho               |
| 3/LUL              | 40                       | 5                   | TED       | MAC/General | Eyelid           | 7                | 4                        | 4                          | No                            | RMR rec/RIR rec           | 8 ET               | Ortho               |
| 4/RUL              | 79                       | 9                   | TED       | General     | Strabismus       | 6                | 3                        | 4                          | No                            | 7 mm BMR                  | 50 ET              | 18 E(T)             |
| 4/LUL              | 79                       | 9                   | TED       | General     | Strabismus       | 5                | 4                        | 4                          | No                            | 7 mm BMR                  | 50 ET              | 18 E(T)             |
| 5/LUL              | 67                       | 29                  | TED       | General     | Eyelid           | 6                | 4                        | 5                          | No                            | RMR rec/RLR<br>resect     | 30 ET              | Ortho               |
| 6/RUL              | 14 <b>AQ2</b>            | 18                  | III Palsy | General     | Strabismus       | -2               | 4                        | 4                          | No                            | 5 mm BMR resect<br>w/ adj | 30 XT              | 8 X(T)              |
| 6/LUL              | 14 <b>AQ2</b>            | 18                  | III Palsy | General     | Strabismus       | -1               | 4                        | 4                          | No                            | 5 mm BMR resect<br>w/ adj | 30 XT              | 8 X(T)              |
| 7/RUL              | 22                       | 7                   | III Palsy | General     | Strabismus       | 0.5              | 3                        | 3                          | No                            | Post fixation MR,<br>IR   | Ortho              | Less<br>diplopia    |
| 8/RUL              | 45                       | 2                   | TED       | MAC         | Eyelid           | 9                | 5                        | 4                          | No                            | 5.0 RMR rec<br>w/ adj     | 6-8 ET,<br>1 LHT   | 1 LHT               |
| 8/LUL              | 45                       | 2                   | TED       | MAC         | Eyelid           | 9                | 5                        | 4                          | No                            | 5.0 RMR rec<br>w/ adj     | 6-8 ET,<br>1 LHT   | 1 LHT               |
| 9/RUL              | 40                       | 4                   | TED       | MAC/General | Eyelid           | 8                | 1                        | 4                          | Yes                           | 3.5 mm BMR<br>w/ adj      | 18 ET              | 8 E(T)              |
| 9/LUL              | 40                       | 16                  | TED       | MAC/General | Eyelid           | 6                | 4                        | 4                          | No                            | 3.5 mm BMR<br>w/ adj      | 18 ET              | 8 E(T)              |

MRD<sub>1</sub> = margin reflex distance; Preop = preoperative; Postop = postoperative; RUL = right upper eyelid; TED = thyroid disease; MAC = monitored anesthesia care; BMR = bilateral medial rectus recession; ET = esotropia; LUL = left upper eyelid; w/adj = with adjustable sutures; ortho = orthophoria; RMR = right medial rectus; rec = recession; RIR = right inferior rectus; ET = intermittent esotropia; RLR = right lateral rectus; resect = resection; III palsy = third cranial nerve palsy; XT = exotropia; X(T) = exotropia at near; MR = medial rectus; IR = inferior rectus; LHT = left hypertropia.



**Figure 1.** (A) Preoperative photograph of patient 8 showing upper eyelid retraction and esotropia. (B) Preoperative photograph of patient 8 after upper eyelid retraction repair and medial rectus recession.



**Figure 2.** (A) Preoperative photograph of patient 9 showing upper eyelid retraction and esotropia. (B) Postoperative photograph of patient 9 after upper eyelid retraction repair and medial rectus recession.

patients were offered adjustable extraocular muscle suture surgery and 4 patients consented to and received it. Four patients underwent bilateral medial rectus recession; in 2 of these patients, adjustable sutures were used. The remaining 5 patients had one of the following: medial and inferior rectus recession, a recess/resect procedure, bilateral medial rectus recession, posterior fixation, and right medial rectus recession. The patients were observed for an average of 11 months (range: 1 to 29 months). Postoperative eyelid measurements and extraocular motility measurements were recorded.

The data are summarized in the table. Postoperatively, 13 of 16 eyelids (81%) achieved an MRD<sub>1</sub> within 1 mm of the target. Three eyelids (20%) required surgical revision. Patient 9 underwent revision surgery of the right upper eyelid, and revision surgery of both upper eyelids was recommended to patient 2. Eight of 9 patients (89%) demonstrated satisfactory strabismus correction as defined above. It should be noted that patient 7 was orthophoric preoperatively but is included as a success because she had an expanded field of binocular vision after posterior fixation of the medial rectus and inferior rectus muscles. There were no complications (Figs. 1 and 2).

## DISCUSSION

This study sought to determine the efficacy of combined eyelid and strabismus surgery in the same setting to avoid a second, staged operation in patients requiring both types of procedures. It particularly sought to determine the efficacy of same-setting surgery involving the horizontal rectus muscles and eyelid surgery. The standards for evaluating the results of strabismus surgery followed by eyelid surgery in the same setting for patients with eyelid and extraocular muscle pathology must be met independently to conclude that this approach is a viable option. Furthermore, neither procedure should compromise the result of the other. We applied these standards to our results.

The tendency of eyelid position to change with strabismus surgery of the vertical rectus muscles has been demonstrated.<sup>2-4</sup> In fact, a greater than 90% incidence of eyelid malposition after vertical rectus muscle surgery has been reported.<sup>4</sup> Our results, with 81% of eyelids within 1 mm of the expected result, are comparable to the success rate for eyelid retraction repair without concurrent strabismus surgery.<sup>9</sup> We conclude that simultaneous eyelid and muscle surgery, in selected cases, does not adversely affect

the outcome of either procedure. Specifically, we found that horizontal rectus muscle surgery can be performed simultaneously with eyelid surgery. We are not able to recommend that vertical rectus muscle surgery be performed simultaneously with eyelid surgery.

Our choice of anesthesia varied based on the patient and indications. The child in our series was operated on under general anesthesia for both eyelid and strabismus surgery. For adults, we recommend performing eyelid surgery first under monitored anesthesia care and then strabismus surgery under either monitored anesthesia care or general anesthesia.

Currently, our recommendations include simultaneous upper eyelid transcutaneous surgery in conjunction with horizontal rectus muscle strabismus surgery. This procedure should follow any necessary orbital surgery. We recommend this approach only in patients who demonstrate stability of eyelid and motility measurements preoperatively. Although 2 patients achieved satisfactory eyelid levels with simultaneous vertical rectus muscle surgery, this sample size does not allow us to include vertical muscle surgery in our recommendations. Specifically, we are not able to recommend simultaneous surgery of a vertical rectus muscle and the contiguous eyelid. We also do not suggest transconjunctival eyelid surgery because of the possibility of adhesions between the palpebral and bulbar conjunctiva, as previously described.<sup>10</sup> We achieved good results in 1 patient with partial third nerve palsy, but we cannot recommend it in patients with complete third nerve palsy.

We feel confident in recommending same-setting eyelid and extraocular muscle surgery in select cases. Further prospective studies may be useful in determining whether the timing of the procedures within the same surgical setting (ie, whether the eyelid or extraocular muscle surgery is the first procedure in a combined case), choice of anesthesia (general anesthesia or monitored anesthesia care with local infiltration for extraocular muscle surgery), and vertical rectus muscle surgery affect the surgical outcomes.

## REFERENCES

1. Tanenbaum M, McCord CD, Nunery W. Graves' ophthalmopathy. In: McCord CD, Tanenbaum M, Nunery WR, eds. *Oculoplastic Surgery*, 3rd ed. New York: Raven Press; 1995:379-415.
2. Jampolsky A. Management of vertical strabismus. In: *Transactions of the New Orleans Academy of Ophthalmology*. New York: Raven Press; 1986:154-157.
3. Lueder GT, Scott WE, Kutschke PJ, Keech RV. Long-term results of adjustable suture surgery for strabismus secondary to thyroid ophthalmology. *Ophthalmology*. 1992;99:993-997.
4. Pacheco EM, Guyton DL, Repka MX. Changes in eyelid position accompanying vertical rectus muscle surgery and prevention of lower lid retraction with adjustable surgery. *J Pediatr Ophthalmol Strabismus*. 1992;29:265-272.
5. Hawes MJ, Dortzbach RK. The microscopic anatomy of the lower eyelid retractors. *Arch Ophthalmol*. 1982;100:1313-1318.
6. Fink WH. An anatomic study of the check mechanism of the vertical muscles of the eyes. *Am J Ophthalmol*. 1957;44:800-809.
7. Jampolsky A. Superior rectus revisited. *Trans Am Ophthalmol Soc*. 1981;79:243-256.
8. Older JJ. Surgical treatment of eyelid retraction associated with thyroid eye disease. *Ophthalmic Surg*. 1991;22:318-322.
9. Karesh JW, Putterman AM. Correction of postoperative eyelid retraction with a simplified levator palpebrae superioris (LPS) muscle recession: analysis of a 10-year experience. *Ophthalmic Surg*. 1987;18:815-820.
10. Simpson WA, Downes RN, Collin JF. Unusual complication of strabismus and lid surgery. *Ophthalm Plast Reconstr Surg*. 1989;5:131-132.

## AUTHOR QUERIES

**Abstract** Per journal style, abstracts should be no more than 250 words. OK as edited?

**AQ1** Please provide the full date of the meeting.

**AQ2** According to the text, the age range was 17 to 79, but according to the table it was 14 to 79. Which is correct?

**Table** Please check abbreviations and definitions for accuracy.